

# Intraorally welded wing abutments supporting full-arch prostheses: A retrospective clinical study

Nicolò Zuffellato<sup>1,A–F</sup>, Maurizio Massariol<sup>1,A–F</sup>, Andrea Gandini<sup>2,A–F</sup>, Sergio Dovigo<sup>1,A–F</sup>

<sup>1</sup> Private practice, Noventa Vicentina, Italy

<sup>2</sup> Private practice, Castel d’Azzano, Italy

A – research concept and design; B – collection and/or assembly of data; C – data analysis and interpretation;

D – writing the article; E – critical revision of the article; F – final approval of the article

Dental and Medical Problems, ISSN 1644-387X (print), ISSN 2300-9020 (online)

*Dent Med Probl.* 2022;59(3):333–341

## Address for correspondence

Sergio Dovigo

E-mail: [info@cmciveneto.it](mailto:info@cmciveneto.it)

## Funding sources

None declared

## Conflict of interest

None declared

## Acknowledgements

None declared

Received on January 13, 2022

Reviewed on April 8, 2022

Accepted on April 26, 2022

Published online on September 12, 2022

## Abstract

**Background.** Delayed loading in the rehabilitation of edentulous patients with an implant-supported prosthesis implies a longer treatment time. It requires additional surgery to uncover the submerged implants, and this may increase patients’ discomfort and morbidity.

**Objectives.** The immediate loading-based technique described in this article involves creating a metal framework by intraorally welding the implants pair by pair, using specific wing abutments. The aim of the study was to investigate the implant-prosthetic success and complication rates of this technique when used to rehabilitate totally edentulous patients.

**Material and methods.** The clinical records of totally edentulous patients were retrospectively evaluated. The prosthetic success rate as well as technical and biological complications were analyzed. Furthermore, the implant survival and success rates were assessed by measuring marginal bone loss (MBL) at the implant, prosthesis and patient levels.

**Results.** The records of 37 patients (284 implants and 43 prostheses) were included in the study. At the last follow-up (45.5 ± 33.6 months), the prosthetic success rate was 100%. Mucositis affected 4 implants (1.4%), while peri-implantitis affected 4 implants (1.4%). Meanwhile, 7 implants (2.5%) showed a lack of early osseointegration. According to the criteria of Albrektsson et al., 271 implants (95.4%) were successful. The average MBL at the implant, prosthesis and patient levels was 0.26 ± 0.42 mm, 0.26 ± 0.19 mm and 0.26 ± 0.18 mm, respectively.

**Conclusions.** The technique described in this article seems to be a viable approach to the rehabilitation of totally edentulous patients through immediate loading. However, these results should be confirmed by appropriately designed prospective and comparative clinical studies.

**Keywords:** dental implants, immediate loading, implant

## Cite as

Zuffellato N, Massariol M, Gandini A, Dovigo S. Intraorally welded wing abutments supporting full-arch prostheses: A retrospective clinical study. *Dent Med Probl.* 2022;59(3):333–341. doi:10.17219/dmp/149470

## DOI

10.17219/dmp/149470

## Copyright

Copyright by Author(s)

This is an article distributed under the terms of the

Creative Commons Attribution 3.0 Unported License (CC BY 3.0)

(<https://creativecommons.org/licenses/by/3.0/>).

## Introduction

The rehabilitation of edentulous patients with an implant-supported prosthesis traditionally involves placing the implants, and then loading the prosthesis after 3–4 months in the mandible and 6–8 months in the maxilla.<sup>1</sup> This stress-free healing period allows for the osseointegration of the implant, minimizing the risk of implant failure and loss.<sup>2</sup> However, delayed loading implies a longer treatment time and additional surgery to uncover the submerged implants, which may increase patients' discomfort and morbidity.<sup>2</sup> For this reason, more recently, immediate and early loading have been studied and found to be, under certain conditions, viable options. They involve delivering the prosthesis within 48 h and between 3 and 12 weeks, respectively, after implant placement, thus reducing the time for functional rehabilitation as well as patients' discomfort and morbidity.<sup>3</sup> Under appropriate conditions, the success rate of the implants placed according to the immediate and early loading protocols is high and similar to that obtained with delayed loading.<sup>2,4</sup> Moreover, immediate loading is associated with low bone loss and good esthetic results.<sup>2,5</sup> Indeed, in two-stage procedures, the prosthesis is loaded after 3–4 months or up to 6–8 months after implant placement, allowing significant bone remodeling to occur during this time.<sup>5,6</sup> Furthermore, in the delayed loading protocol, surgical reoperations for prosthesis delivery could bring additional trauma and tissue damage, leading to a greater marginal bone loss (MBL).<sup>6</sup> On the contrary, in the immediate loading procedures there is no second surgery and no delay time between the 2 stages, which reduces bone stress; immediate/early mechanical loading may have a positive effect on the initial phase of healing and may stimulate the formation of the alveolar bone.<sup>6</sup>

The micromovements of fixtures must not exceed 100–150  $\mu\text{m}$  immediately after placement to ensure success, regardless of the loading type. Indeed, osseointegration does not occur if this happens, and fibrous tissue may develop at the bone–implant interface, leading to implant failure.<sup>7</sup> Therefore, adequate primary stability is necessary to achieve success in implant-prosthetic rehabilitation. The success of immediately loaded implants is also affected by the design of the prosthesis, the material it is made of and the way it is connected to the implants. Metal-ceramic prostheses are currently one of the most recommended solutions for several reasons, including their high marginal precision, long duration and excellent bond with the ceramic coating, as well as the possibility to use different modeling techniques.<sup>8</sup> However, new interesting prosthetic materials are emerging; they show advantageous properties, especially with regard to temporary prostheses and immediate loading. For example, semi-crystalline poly-ether-ether-ketone and its various formulations have an elastic modulus that is similar to that of the cortical bone, which reduces the occlusal

forces acting on the prosthesis.<sup>8</sup> Increasing the durability and esthetics of this material would bring an extremely interesting alternative to metal-ceramic in the near future.<sup>8</sup>

Another important aspect of the success of implant-prosthetic rehabilitation through immediate loading is the connection between the implants and the prosthesis. In fact, no residual tensions should exist, as these might be transferred to the bone–implant interface, jeopardizing osseointegration.<sup>7,9</sup> A lack of residual tension also contributes to preventing technical complications, such as screw loosening and/or breaking, as well as abutment fractures.<sup>10,11</sup> The implant splinting technique has proven to be useful for increasing the mechanical stability of the implants and impression precision, which is necessary to fabricate an accurately fitting prosthesis.<sup>10,12,13</sup> Accordingly, several authors have advocated the use of a titanium bar to connect all of the abutments, especially when addressing total edentulism. The prefabricated bar is first modeled to fit the abutments, and then welded directly inside the oral cavity.<sup>13,14</sup> However, this modeling procedure is challenging, since rigid cross-arch stabilization has to be obtained without inducing torsional stress to any of the implants, while adjustments made to one position may induce residual tensions elsewhere along the bar.<sup>13</sup> Alternative approaches involving splinting the adjacent abutments pair by pair might be equally viable in achieving appropriate stabilization while eliminating passive tensions and allowing adequate stress distribution, thus effectively addressing these practical issues. The authors have been rehabilitating fully edentulous patients using the pair-by-pair splinting approach followed by immediate loading for several years. However, they have never studied the 2 techniques systematically with respect to their clinical outcomes. Therefore, the aim of the present study was to retrospectively investigate the viability of this approach in terms of safety and implant and prosthetic success over a medium-term follow-up period while preliminarily assessing the hypothesis that both techniques (pair-by-pair splinting and immediate loading) are similar to other full-arch abutment-splinting approaches.

## Objectives

This study aimed to assess the success of full-arch definitive prosthetic rehabilitation achieved using the pair-by-pair splinting and immediate loading techniques. For this purpose, technical (prosthesis unscrewing, chipping or fracture, screw loosening or fracture, welding points fracture) and biological (non-osseointegration, peri-implantitis, mucositis) complications were evaluated. The secondary objective of the study was to assess the success and survival rates of implant-supported prostheses fabricated using the technique under investigation. This was evaluated by measuring MBL and implant success based on the criteria of Buser et al.,<sup>15</sup> modified by Albrektsson et al.<sup>16,17</sup> These are as follows: the implant

should be immobile when tested clinically; the implant area should not show any signs of persistent pain, dysesthesia or paresthesia; the implant area should not be affected by peri-implant infections; and peri-implant bone resorption should be less than 1.5 mm during the first year after loading or 0.2 mm/year during the following years. Implants were considered successful when all the abovementioned conditions were met.

## Material and methods

The authors retrospectively assessed the clinical data of patients who were rehabilitated for total edentulism by means of the pair-by-pair splinting technique followed by immediate loading, described in the next paragraph, between 2003 and 2020 at an Italian private dental clinic in Noventa Vicentina. The patients were followed up at the same clinic through periodic routine control visits. The study protocol was assessed and approved by the Internal Ethics Commission of the Clinic. Due to the retrospective nature of the study, the Commission did not deem it necessary to ask for an approval by a third-party Ethics Committee. The records were selected if the patient met the following criteria: aged 18–85 years; had been rehabilitated for total edentulism using the technique of interest; had had no previous surgical procedure for bone grafting or bone regeneration; had not received any peri-implant bone regeneration at implant placement; had been followed up for at least 14 months after implant placement; and had given their informed consent before treatment for the use of their clinical data for subsequent clinical studies. In addition, the clinical records had to include the intraoral radiographs collected after implant insertion and at the last follow-up visit with the use of a customized silicone bite and a Rinn centering device. The data was excluded if the patient was suffering from osteoporosis or any other diseases that affect bone metabolism, was undergoing bisphosphonate therapy, was suffering from neoplasia or a psychiatric disease, had a history of chemotherapy or radiotherapy in the head or neck region, was immunocompromised, had coagulation disorders, suffered from acute oral infections, was pregnant, was a moderate to heavy smoker (>10 cigarettes/day), had a history of drug or alcohol abuse, or was taking any drug that could interfere with the osseointegration process.

### Surgical and implant placement protocol

All patients underwent a clinical examination, and radiographic assessment was performed using cone-beam computed tomography (CBCT) and panoramic X-rays. All patients were prescribed antibiotic prophylaxis (2 g amoxicillin/clavulanic acid (Augmentin®); GlaxoSmithKline, Verona, Italy) 1 h before surgery and every 12 h for 8–10 days post-surgery.

In addition, postoperative care included mouth rinses with chlorhexidine 0.2% (Corsodyl®; GlaxoSmithKline) for up to 2 weeks after surgery and pain medication (500 mg naproxen sodium (Synflex®); Recordati, Milan, Italy) 2–4 times a day for 7 days after a surgical intervention.

Surgical procedures were carried out under local anesthesia using articaine hydrochloride (40 mg/mL) with epinephrine 1:100,000 (Citocartin®; Molteni Dental, Milan, Italy). After elevating a full-thickness flap, the implants were placed in the planned positions according to the manufacturer's instructions. All of the provisional and definitive prostheses were made of the same material and manufactured by the same technician. The pair-by-pair splinting technique followed by immediate loading was used to rehabilitate the patients. Intraoral radiographs were taken immediately after loading (at the provisional prosthesis delivery) and 6 months later (at the definitive prosthesis delivery), with additional radiographic assessment performed at least every 12 months thereafter. At each control visit, the prosthesis was unscrewed to provide the patient with adequate hygiene, which allowed for the assessment of implant osseointegration, and signs of peri-implantitis and mucositis.

### Pair-by-pair splinting and immediate loading technique

The splinting technique involved using special abutments with protruding lateral extensions (Wings®; T.A.B., Borso del Grappa, Italy). These structures were first screwed to the implants. After that, the lateral 'wings' were cut to the desired length to partially overlap those of the adjacent implants, and then they were welded intraorally. The resulting metal structure constituted the internal reinforcement of the provisional prosthesis, which was delivered to the patient immediately after implant surgery. The whole procedure is being marketed in Italy under the "Instantaneous Loading Technique" trademark.

In detail, the technique involves fabricating the provisional and definitive prostheses directly in the patient's mouth over a metal structure (Fig. 1). The metal support is made of several wing abutments, available in different lengths (1.7 mm, 2.7 mm and 4.5 mm), which are connected to the implants by means of 20-millimeter-long screws and welded to each other to connect the adjacent implants. The abutment lateral extensions (i.e., the wings) are 11.5 mm wide and have different angles (30°, 45°, flat). The extensions are cut to the desired length to partially overlap those of the adjacent implants, and then they are welded. The protruding parts are convex on the buccal side and flat on the vestibular side. This configuration limits the contact area between the two wings, which increases the electric resistance between the two metal pieces. During intraoral welding, specific current is applied; it leads to the release of heat at the contact point, allowing a strong weld between the two wings.



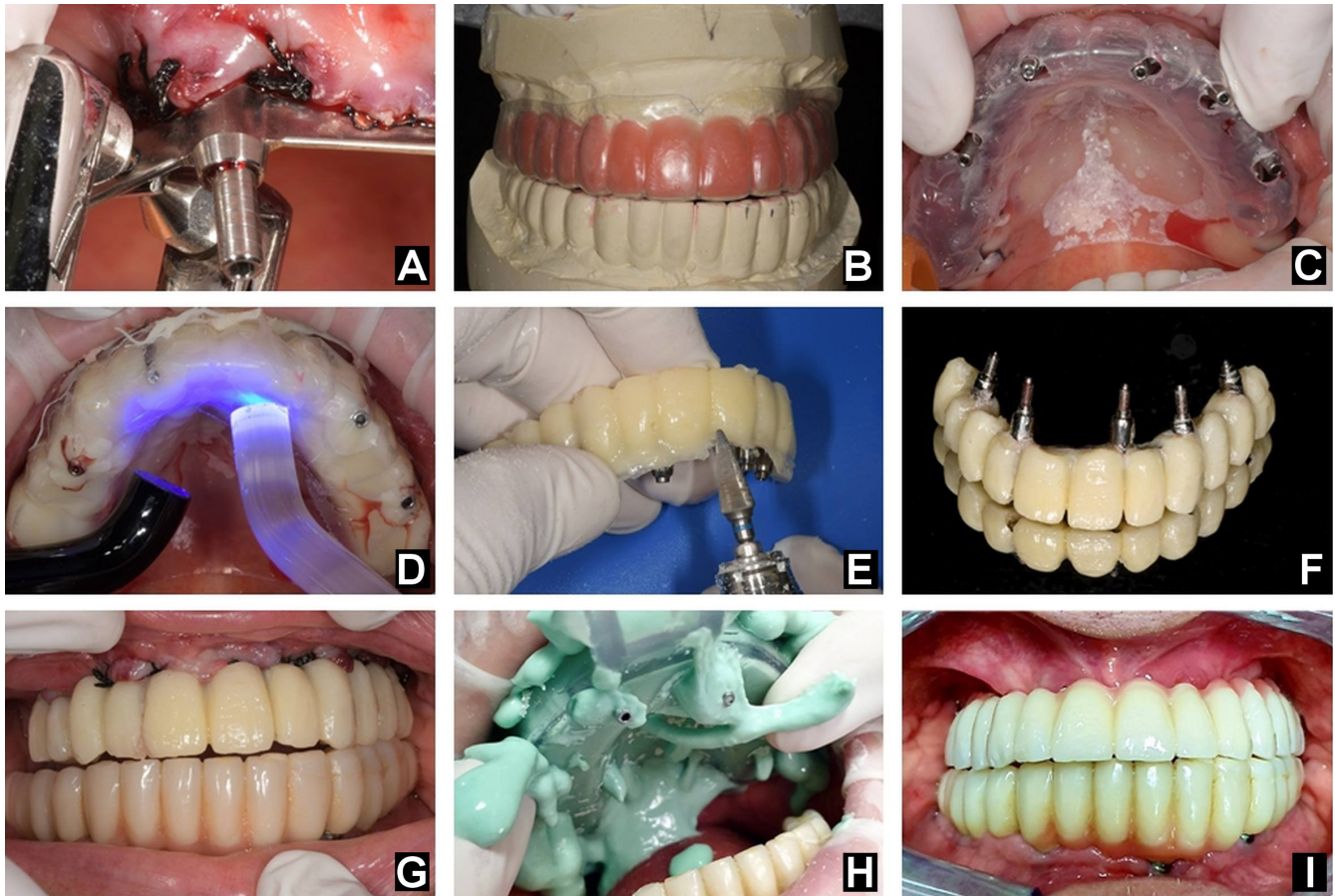


Fig. 1. The main steps of the Instantaneous Loading Technique

A – intraoral welding of the wing abutments; B,C – producing and positioning of the prosthetic thermoplastic template; D – photopolymerization of the resin; E,F – smoothing and finishing of the provisional prosthesis; G – provisional prosthesis delivered to the patient; H – alginate impression of the definitive metal framework; I – definitive prosthesis delivered to the patient.

The provisional prosthesis is delivered immediately after the metal structure is welded. First, a prosthetic thermoplastic template is shaped according to the diagnostic waxing obtained from the alginate impression of the arch of interest. Then, the template is positioned on the welded structure in the oral cavity and holes are drilled to accommodate pass-through screws. Subsequently, the template with the protruding screws is filled with a photopolymerizing resin. Once the resin has set, the prosthesis is smoothed, finished and screwed to the metal structure. The definitive prosthesis is delivered after 6 months. A new wing metal structure is created and an alginate impression is taken. Alginate was chosen for all impressions, since it is a low-cost material and it is easy to manipulate while allowing performing a detailed impression in one step. Moreover, it is well tolerated by the patient, the instrumentation is very simple and it takes a short time to prepare the impression. This is particularly important considering that the prosthesis has to be fabricated immediately after implant placement and metal structure welding. Based on this new metal structure, the technician fabricates the definitive prosthesis using a composite resin, which is supported and reinforced by the embedded new metal structure. The prosthesis is screwed onto the

implants with a torque of 35 N-cm. Lastly, using the same composite resin as in the prosthesis, the screw holes are filled. Figure 2 shows a representative case.

### Measurement of marginal bone loss

Marginal bone loss was measured on intraoral radiographs, after digitizing them at 600 dpi, using image analysis software (ImageJ, National Institutes of Health, Bethesda, USA; <https://imagej.nih.gov/ij>). The software was calibrated according to the known dimensions of the implants, with the implant diameter at the most coronal part of the implant neck used as a reference. Measurements were taken with an accuracy of 0.01 mm. The peri-implant marginal bone level (PBL) at a given time point was calculated as the average of the distance, measured at the mesial and distal sides of the implant, between the implant–abutment interface and the most apical point of the crestal bone that was in contact with the implant itself. Marginal bone loss that occurred between the 2 time points of interest was then calculated as the difference between the 2 corresponding PBL values.

In this study, MBL was calculated as the difference between PBL at the last follow-up and that at the definitive

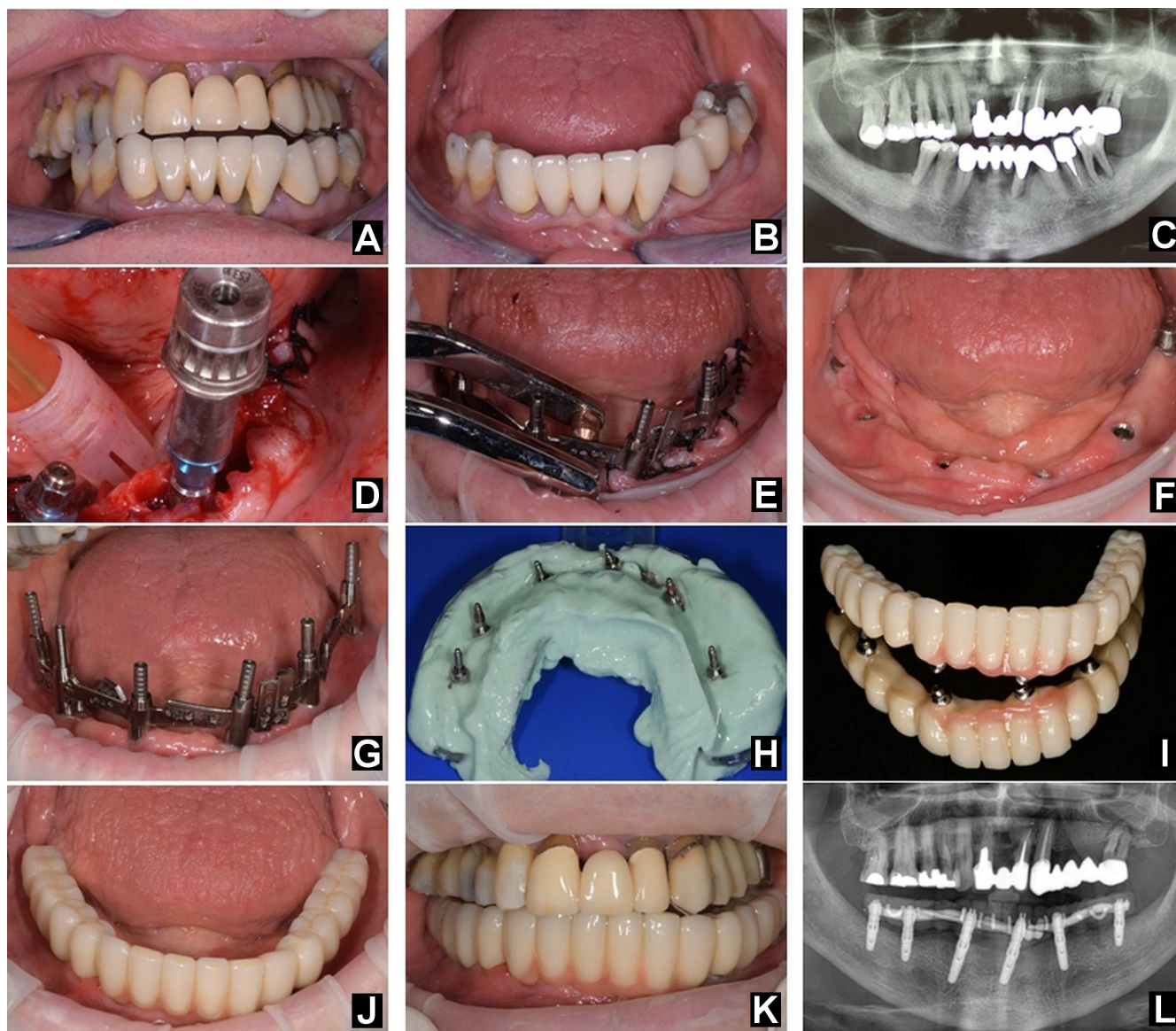


Fig. 2. Representative case

A,B – patient at clinical presentation; C – pre-surgical radiographic assessment; D – implant placement; E – welding of the wing abutments; F – soft tissue healing after 6 months; G – definitive titanium wing framework; H – alginate impression embedding the titanium structure; I – definitive prosthesis; J,K – definitive prosthesis delivered to the patient; L – orthopantomogram (OPG) after 6 months.

prosthesis delivery. This was done at the patient, implant and prosthesis levels. At the patient level, the mean MBL was calculated by averaging the MBL of all the patient's implants. At the implant level, the mean MBL was calculated by averaging all MBL values for all implants. At the prosthesis level, the mean MBL was calculated as the average of the MBL of all the implants supporting the same prosthesis.

## Bias

The possible sources of bias included the fact that the retrospective analysis concerned patients treated by one of the authors (SD). Additionally, clinical records were selected and data was extracted by the 3 other authors (NZ, MM, AG). Statistical analysis was conducted by an independent biostatistician.

## Statistical analysis

As the purpose of the study was limited to investigating the viability of the immediate loading technique by means of descriptive statistics, no sample size calculation was performed. Therefore, the number of clinical records considered was that of the available records that met the study inclusion criteria.

Discrete variables (the patients' gender, and the number of implants and prostheses) were summarized by means of absolute and relative frequencies ( $n$  (%)). The distribution of continuous variables (the patient's age, the follow-up time and MBL) was first tested for normality using the Shapiro–Wilk test. Then, the variables were summarized as mean and standard deviation ( $M \pm SD$ ) or as mean and standard error of the mean ( $M \pm SEM$ ) if normal, or as



median and interquartile range (*Me (IQR)*) if non-normal. As some patients underwent 2 surgical procedures for implant placement, one for each dental arch, and at different times, only the age of the patient at the 1<sup>st</sup> surgery was considered for statistical purposes. Follow-up duration was calculated both at the implant and patient level; in the latter case, the longest follow-up was considered, corresponding to the time between the last control visit and the placement of the first implant. The complication rates were calculated considering the patients, the implants and the prosthesis as statistical units. Statistical analysis was performed using standard software (Origin(Pro), v. 2022; OriginLab Corporation, Northampton, USA).

## Results

Thirty-seven records concerning 16 men (43.2%) and 21 women (56.8%), 284 implants and 43 prostheses were included in the study. The mean patient age at the 1<sup>st</sup> surgery was  $65.2 \pm 8.3$  (50–85) years. As many as 84% of patients received 1 prosthesis and 16% received 2, one for each dental arch. A total of 94 implants (33.1%) were placed in the maxilla and 190 (66.9%) in the mandible. Between 4 and 9 implants were placed in each arch, and the percentages of prostheses supported by a given number of implants are reported in Table 1. Thirty-nine prostheses spanned from dental position 17 to dental position 27 in the maxilla and from dental position 37 to dental position 47 in the mandible. Four prostheses spanned from position 16 to position 26 in the maxilla and from position 36 to position 46 in the mandible. Ten prostheses were cantilevered, with the extensions spanning one element at one or both sides (Table 2).

The implants had different diameters (3.20, 3.25, 3.30, 3.70, 4.00, 4.10, and 5.00 mm) and lengths (8.50, 10.00, 11.00, 11.50, 13.00, and 15.00 mm). The models and brands were as follows: BTK<sup>®</sup> ( $n = 225$ ; Biotec, Povolario, Italy); Osseotite<sup>®</sup> ( $n = 31$ ; Biotech, Vicenza, Italy); Normomix<sup>®</sup> ( $n = 14$ ; Or-Vit Viteria Ortopedica, Castel Maggiore, Italy); and ShapeOne<sup>®</sup> ( $n = 14$ ; iRES SAGL, Mendrisio, Switzerland). Although implants from different manufacturers were used, all were tapered and had

**Table 1.** Distribution of prostheses according to the number of implants they were supported by

No. of implants for each arch	No. of prostheses $n$ (%)
4	1 (2.3)
5	7 (16.3)
6	12 (27.9)
7	14 (32.6)
8	6 (14.0)
9	3 (7.0)
Total	43 (100.0)

**Table 2.** Distribution of prostheses according to their spanning and cantilevers

Cantilevers	Spanning from 17 to 27/ from 37 to 47	Spanning from 16 to 26/ from 36 to 46	Total
Non-cantilevered	33 (76.7)	0 (0.0)	33 (76.7)
Cantilevered (one-unit extension at one side)	4 (9.3)	0 (0.0)	4 (9.3)
Cantilevered (one-unit extension at both sides)	2 (4.7)	4 (9.3)	6 (14.0)
Total	39 (90.7)	4 (9.3)	43 (100.0)

Data presented as number (percentage) ( $n$  (%)).

a sandblasted, double-etched surface. The patients were followed up for a mean period of  $45.5 \pm 33.6$  months (range: 14.0–217.0; 40.0 (23.0–57.0)), and the average follow-up time for implant insertion and prosthesis loading was  $45.0 \pm 31.9$  months (range: 14.0–217.0; 44.0 (22.5–56.0)).

## Outcome data

After implant placement and prosthesis loading, 1 patient (2.7%) complained of pain associated with inflammation and redness of the mucosa at 1 implant site (0.4%). Mucositis affected 1 patient (2.7%) and 4 implants (1.4%). Peri-implantitis affected 2 patients (5.4%) at 4 implants (1.4%); in 2 cases, one for each patient, 1 implant was lost (0.7%). Seven implants (2.5%) in 6 patients (16.2%) showed a lack of early osseointegration, which led to implant loss in 6 cases (2.1%) in 5 patients (13.5%). Two implants (0.7%) in 1 patient (2.7%) showed peri-implant radiolucency (Table 3).

Minor technical complications occurred in 6 prostheses (14.0%) of 3 patients (8.1%). Four cases (9.3%) involving 3 patients (8.1%) regarded a minor fracture of the composite material. Two of these (4.7%) involved the same patient (2.7%) and concerned the provisional restoration. In 2 cases (4.7%) regarding 1 patient (2.7%), the wear of the prosthesis occurred. In all cases, the defects were easily solved on the same day of the control visit and did not require the substitution of the prosthesis. Therefore, the success rate of the definitive prostheses can be considered to be 100%. No fracture of the welding points occurred. Furthermore, no screws were fractured or lost (Table 4).

**Table 3.** Biological complications by patient and by implant

Biological complication	Patients $N = 37$	Implants $N = 284$
Pain	1 (2.7)	1 (0.4)
Mucositis	1 (2.7)	4 (1.4)
Peri-implantitis	2 (5.4)	4 (1.4)
Peri-implant radiolucency	1 (2.7)	2 (0.7)
Lack of early osseointegration	6 (16.2)	7 (2.5)
Lost implants	5 (13.5)	6 (2.1)

Data presented as  $n$  (%).

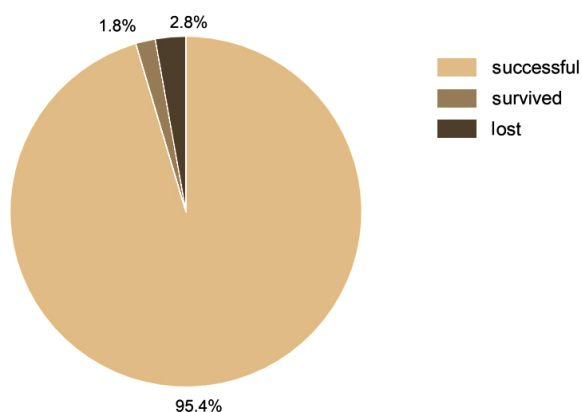
**Table 4.** Technical complications by patient and by prosthesis

Technical complication	Patients N = 37	Protheses N = 43
Prosthesis fracture	0 (0.0)	0 (0.0)
Minor fracture of the composite material	3 (8.1)	4 (9.3)
Prosthesis wear	1 (2.7)	2 (4.7)
Fracture at the welding points	0 (0.0)	0 (0.0)
Screw fracture	0 (0.0)	0 (0.0)
Unscrewing	0 (0.0)	0 (0.0)

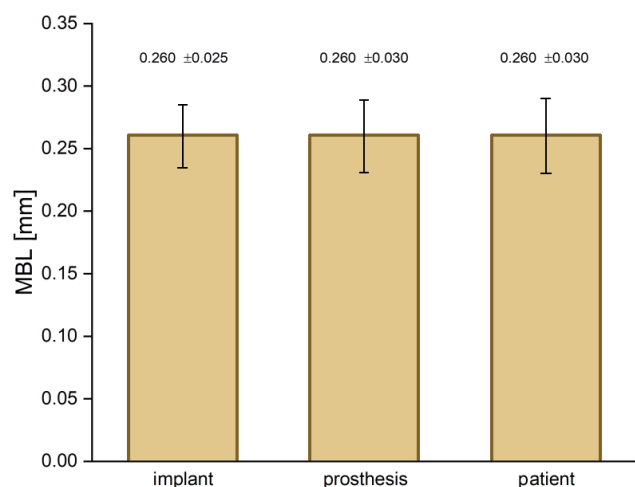
Data presented as *n* (%).

According to the criteria of Buser et al.,<sup>15</sup> modified by Albrektsson et al.,<sup>16,17</sup> 271 implants (95.4%) were successful. Of the 13 implants that were not, 5 (1.8%) survived and 8 (2.8%) were lost (Fig. 3).

At the last follow-up, the average MBL at the implant level was  $0.26 \pm 0.42$  mm (range: 0.00–2.83), at prosthesis level it was  $0.26 \pm 0.19$  mm (range: 0.00–0.90) and at the patient level it was  $0.26 \pm 0.18$  mm (range: 0.00–0.90) (Fig. 4).



**Fig. 3.** Implant success at the last follow-up  
According to the criteria of Albrektsson et al.<sup>16,17</sup>



**Fig. 4.** Marginal bone loss (MBL) at the last follow-up, calculated at the implant, prosthesis and patient levels

Data presented as mean  $\pm$  standard error of the mean ( $M \pm SEM$ ) for the sake of clarity.

## Discussion

The results of the present study show that the technique under investigation allows the successful rehabilitation of totally edentulous patients over a medium-term follow-up period without severe complications. Almost 4 years after treatment, the implant survival and success rates were 97.2% and 95.4%, respectively. These values are similar to those reported in the literature on immediate loading. Indeed, a systematic review conducted by Del Fabbro et al. in 2019 evaluated 5,349 implants immediately loaded in 1,738 patients and reported a mean implant survival of 97.4% at a mean follow-up of 72.4 months.<sup>18</sup> A similar survival rate (97.7%) was previously observed by Rivaldo et al. after 18 months since loading in 33 patients with totally edentulous mandibles.<sup>19</sup> The rehabilitation involved a complete, immediately loaded, fixed prosthesis supported by 3 implants for each patient.<sup>19</sup> Primo et al. reported a 95.3% success rate in 20 completely edentulous patients at a mean follow-up of 66.8 months.<sup>20</sup> The patients were treated using the immediate loading, three-implant-supported prosthesis rehabilitation protocol.<sup>20</sup> In a comparative clinical study, Alfadda achieved similar results (96% of success) 1 year post-surgery after rehabilitating 45 patients, in whom 160 immediately loaded implants were inserted.<sup>21</sup>

The implant survival and success rates of the present study may appear slightly lower than those obtained in other studies using a similar abutment-splinting technique. Degidi et al. reported a 100% implant success at a 12-month follow-up examination in 20 patients who had received 153 implants that were fixed with an intraorally welded titanium bar.<sup>22</sup> The same authors prospectively treated 20 patients who received 80 interforaminal implants in edentulous mandibles.<sup>23</sup> After implant placement, the abutments were connected to the implants and welded to a titanium bar. Subsequently, the definitive prosthesis was screwed onto the metal framework. The implant survival rate was 100% at a 24-month follow-up.<sup>23</sup> The same survival rate was also observed by Albiero et al. 1 year after surgery in 10 consecutive patients treated with the guided-welded approach.<sup>24</sup> According to this protocol, the implants were inserted using computer-assisted surgery and immediately loaded with a full-arch prosthesis supported by an intraorally welded titanium structure.<sup>24</sup> However, even though the survival and success rates of the abovementioned studies were slightly higher than those obtained in the present study, the mean follow-up periods of these works were shorter, being limited to 12–24 months, and the results relate to fewer implants and patients. These facts may explain the apparent difference in outcome. As a whole, the present results seem to be in line with those reported in the literature.

In this study, the definitive restoration was successful in 100%. Indeed, technical complications concerned a minor superstructure fracture and the wear of the prosthesis, involving no more than 1 element, and were easily repaired

without compromising the function of the dentures. Several previous studies on immediate loading, both on implant-supported prostheses in general and on metal welded structures in particular, showed comparable results. Klee de Vasconcellos et al. reported a 100% prosthetic success in 40 patients with edentulous mandibles treated with a fixed denture supported by an intraorally welded titanium bar.<sup>25</sup> Similarly, Degidi et al. rehabilitated 40 patients with edentulous mandibles using a fixed restoration supported by an intraoral welded metal structure.<sup>14</sup> The prosthetic survival rate was 100% at a 24-month follow-up. However, 2 patients reported the fracture of the acrylic resin superstructure, though this did not compromise the function of the prostheses, which were easily repaired.<sup>14</sup> The prosthetic success rate was also 100% in a study by Marchesi et al., who rehabilitated 17 patients with 2 parallel and 2 tilted implants in an edentulous maxilla.<sup>26</sup> They were immediately loaded with fixed prostheses and were followed up for an average of 26.5 months.<sup>26</sup>

Soft tissue complications were observed in only 2 cases in this study and they were not of particular relevance. One patient had mild inflammation and redness of the mucosa at 1 implant site, and complained about mild pain, which resolved spontaneously, whereas another patient had mucositis at 4 implant positions. Moreover, the same patient presented radiographic radiolucency and peri-implantitis at 4 other implant sites. This patient (59 years old at the time of surgery) was a smoker (10 cigarettes/day) and had a history of periodontal diseases since youth. Considering her partially compromised oral conditions, the patient had been offered rehabilitation with a removable prosthesis, but she declined and asked for a fixed implant-supported one. She was advised about the risk, but accepted anyway, and was finally satisfied with the result.

The mean MBL observed in the present study after an average of 45 months since loading (0.26 mm) was lower than that reported by Klee de Vasconcellos et al. (1.11 mm at 18 months),<sup>25</sup> Degidi et al. (0.57 at 12 months)<sup>22</sup> and Degidi et al. (0.59 mm at 24 months).<sup>14</sup> This suggests that the technique under investigation allowed the creation of a precise and passively fitting structure, shaped in accordance with the anatomy of each individual patient, and did not induce stress to the underlying bone. This may favor the osseointegration of implants, and thereby the success of the implant-prosthetic rehabilitation of edentulous patients. However, a clear comparison between the MBL values observed in this study and those previously mentioned cannot be firmly sustained given the different surgical and prosthetic protocols used.

Overall, the current results suggest that splinting the adjacent implants in pairs, according to the technique under investigation, may be a good solution to achieve a passive fit between the restoration and the implants while avoiding severe biological and technical complications. This technique is easy and fast to perform, especially as the wing abutment extensions are provided with different

angles, which allows the shaping of the metal frame to the specific anatomy of each patient. Furthermore, the cost of this approach is lower as compared to other rehabilitation procedures. It might therefore be a fair option, with acceptable esthetic and functional outcomes, for those who cannot afford more expensive treatment.

## Limitations

The main limitation of this study is that it was retrospective. This means that the results might be biased by a number of confounding variables that could not be controlled, including the heterogeneity of the implant brands being used, the different number of implants supporting the prostheses and the presence of some cantilevered prostheses. Also, all patients were treated by the same surgeon at a single clinic. Furthermore, the present use of intraoral radiographs to assess implant success and survival is not sufficient to determine osseointegration on its own, which may limit the validity of the present results. Therefore, comparisons between the present results and those in the literature on immediate loading and similar techniques should be made with caution, and generalizing the results should be limited to some extent.

The most important advantage of the pair-by-pair system over classical approaches is the rapid element welding, which obviates the usually cumbersome need to cut and bend a bar. Prospective studies, choosing specific covariates other than the technique itself, are necessary to assess the performance and safety of this approach without bias. Comparative studies are also warranted to assess whether the technique provides any advantage over other splinting techniques associated with immediate loading.

## Conclusions

Within the limitations of the present study, the immediate loading technique used by the authors seems to be a valid option for the rehabilitation of totally edentulous patients. This approach allowed high implant-prosthetic success without severe biological and technical complications. It appears to be as easy, fast, inexpensive, safe, and effective as other rehabilitation procedures involving the fixation of implants with intraorally welded metal bars. However, this should be further assessed by appropriately designed prospective and comparative clinical studies.

## Ethics approval and consent to participate

The study protocol was assessed and approved by the Internal Ethics Commission of the Clinic (a private dental clinic in Noventa Vicentina, Italy). The patients had given their informed consent before treatment for the use of their clinical data for subsequent clinical studies (one of the inclusion criteria).



## Data availability

The datasets generated and/or analyzed during the current study are available from the corresponding author on reasonable request.

## Consent for publication

Not applicable.

## ORCID iDs

Nicolò Zuffellato  <https://orcid.org/0000-0003-2986-1333>  
 Maurizio Massariol  <https://orcid.org/0000-0001-5454-7341>  
 Andrea Gandini  <https://orcid.org/0000-0001-5046-7248>  
 Sergio Dovigo  <https://orcid.org/0000-0002-0177-1910>

## References

- Weerapong K, Sirimongkolwattana S, Sastraruji T, Khongkhunthian P. Comparative study of immediate loading on short dental implants and conventional dental implants in the posterior mandible: A randomized clinical trial. *Int J Oral Maxillofac Implants*. 2019;34(1):141–149. doi:10.11607/jomi.6732
- Zhang S, Wang S, Song Y. Immediate loading for implant restoration compared with early or conventional loading: A meta-analysis. *J Craniomaxillofac Surg*. 2017;45(6):793–803. doi:10.1016/j.jcms.2016.05.002
- Galli F, Capelli M, Zuffetti F, Testori T, Esposito M. Immediate non-occlusal vs. early loading of dental implants in partially edentulous patients: A multicentre randomized clinical trial. Peri-implant bone and soft-tissue levels. *Clin Oral Implants Res*. 2008;19(6):546–552. doi:10.1111/j.1600-0501.2008.01530.x
- García-Sánchez R, Dopico J, Kalemaj Z, Buti J, Zamora GP, Mardas N. Comparison of clinical outcomes of immediate versus delayed placement of dental implants: A systematic review and meta-analysis. *Clin Oral Implants Res*. 2022;33(3):231–277. doi:10.1111/clr.13892
- Borges GA, Costa RC, Nagay BE, et al. Long-term outcomes of different loading protocols for implant-supported mandibular overdentures: A systematic review and meta-analysis. *J Prosthet Dent*. 2021;125(5):732–745. doi:10.1016/j.prosdent.2020.04.017
- Liu W, Cai H, Zhang J, Wang J, Sui L. Effects of immediate and delayed loading protocols on marginal bone loss around implants in unsplinted mandibular implant-retained overdentures: A systematic review and meta-analysis. *BMC Oral Health*. 2021;21(1):122. doi:10.1186/s12903-021-01486-3
- Kohli N, Stoddart JC, van Arkel RJ. The limit of tolerable micro-motion for implant osseointegration: A systematic review. *Sci Rep*. 2021;11(1):10797. doi:10.1038/s41598-021-90142-5
- Reda R, Zanza A, Galli M, De Biase A, Testarelli L, Di Nardo D. Applications and clinical behavior of BioHPP in prosthetic dentistry: A short review. *J Compos Sci*. 2022;6(3):90. doi:10.3390/jcs6030090
- Ghoul WE, Chidiac JJ. Prosthetic requirements for immediate implant loading: A review. *J Prosthodont*. 2012;21(2):141–154. doi:10.1111/j.1532-849X.2011.00819.x
- Papaspyridakos P, Chen CJ, Gallucci GO, Doukoudakis A, Weber HP, Chronopoulos V. Accuracy of implant impressions for partially and completely edentulous patients: A systematic review. *Int J Oral Maxillofac Implants*. 2014;29(4):836–845. doi:10.11607/jomi.3625
- Sakka S, Baroudi K, Nassani MZ. Factors associated with early and late failure of dental implants. *J Investig Clin Dent*. 2012;3(4):258–261. doi:10.1111/j.2041-1626.2012.00162.x
- Moreira AH, Rodrigues NF, Pinho AC, Fonseca JC, Vilaça JL. Accuracy comparison of implant impression techniques: A systematic review. *Clin Implant Dent Relat Res*. 2015;17(Suppl 2):e751–e764. doi:10.1111/cid.12310
- Degidi M, Gehrke P, Spanel A, Piattelli A. Syncrystallization: A technique for temporization of immediately loaded implants with metal-reinforced acrylic resin restorations. *Clin Implant Dent Relat Res*. 2006;8(3):123–134. doi:10.1111/j.1708-8208.2006.00011.x
- Degidi M, Nardi D, Piattelli A. Immediate rehabilitation of the edentulous mandible with a definitive prosthesis supported by an intraorally welded titanium bar. *Int J Oral Maxillofac Implants*. 2009;24(2):342–347. PMID:19492651.
- Buser D, Weber HP, Brägger U, Balsiger C. Tissue integration of one-stage implants: Three-year results of a prospective longitudinal study with hollow cylinder and hollow screw implants. *Quintessence Int*. 1994;25(10):679–686. PMID:9161245.
- Albrektsson T, Zarb G, Worthington P, Eriksson AR. The long-term efficacy of currently used dental implants: A review and proposed criteria of success. *Int J Oral Maxillofac Implants*. 1986;1(1):11–25. PMID:3527955.
- Albrektsson T, Zarb GA. Determinants of correct clinical reporting. *Int J Prosthodont*. 1998;11(5):517–521. PMID:9922743.
- Del Fabbro M, Testori T, Kekovic V, Goker F, Tumedei M, Wang HL. A systematic review of survival rates of osseointegrated implants in fully and partially edentulous patients following immediate loading. *J Clin Med*. 2019;8(12):2142. doi:10.3390/jcm8122142
- Rivaldo EG, Montagner A, Nary H, da Fontoura Frasca LC, Brånemark PI. Assessment of rehabilitation in edentulous patients treated with an immediately loaded complete fixed mandibular prosthesis supported by three implants. *Int J Oral Maxillofac Implants*. 2012;27(3):695–702. PMID:22616065.
- Primo BT, Mezzari LM, da Fontoura Frasca LC, Linderman R, Rivaldo EG. Clinical and radiographic assessment of three-implant-supported fixed-prosthesis rehabilitation of the edentulous mandible: Immediate versus delayed loading. *Int J Oral Maxillofac Implants*. 2018;33(3):653–660. doi:10.11607/jomi.5870
- Alfadda SA. A randomized controlled clinical trial of edentulous patients treated with immediately loaded implant-supported mandibular fixed prostheses. *Clin Implant Dent Relat Res*. 2014;16(6):806–816. doi:10.1111/cid.12057
- Degidi M, Nardi D, Piattelli A. Immediate loading of the edentulous maxilla with a final restoration supported by an intraoral welded titanium bar: A case series of 20 consecutive cases. *J Periodontol*. 2008;79(11):2207–2213. doi:10.1902/jop.2008.080141
- Degidi M, Nardi D, Piattelli A. Prospective study with a 2-year follow-up on immediate implant loading in the edentulous mandible with a definitive restoration using intra-oral welding. *Clin Oral Implants Res*. 2010;21(4):379–385. doi:10.1111/j.1600-0501.2009.01865.x
- Albiero AM, Benato R, Benato A, Degidi M. Use of intraoral welding to increase the predictability of immediately loaded computer-guided implants. *Int J Periodontics Restorative Dent*. 2017;37(4):591–598. doi:10.11607/prd.3027
- Klee de Vasconcellos D, Bottino MA, Saad PA, Faloppa F. A new device in immediately loaded implant treatment in the edentulous mandible. *Int J Oral Maxillofac Implants*. 2006;21(4):615–622. PMID:16955614.
- Marchesi M, Ferrari C, Superbi S, Jimbo R, Galli S. Modified protocol of the intraoral welding technique for immediate implant-supported rehabilitation of the edentulous maxilla. *Implant Dent*. 2015;24(1):110–116. doi:10.1097/ID.0000000000000189